

## Salinomycin-induced Polyneuropathy in Cats: Morphologic and Epidemiologic Data

J. S. VAN DER LINDE-SIPMAN, T. S. G. A. M. VAN DEN INGH, J. J. VAN NES, H. VERHAGEN,  
J. G. T. M. KERSTEN, A. C. BEYNEN, AND R. PLEKCRINGA

Departments of Pathology, (JSL, TSGAMI) and Clinical Sciences of Companion Animals, (JJN, ACB),  
Faculty of Veterinary Medicine, Utrecht University, Utrecht, The Netherlands;  
Netherlands Organization for Applied Scientific Research, Nutrition and Food Research Institute,  
Zeist, The Netherlands (HV, JGTMK); and  
Spillers Petfoods Benelux BV, Barneveld, The Netherlands (RP)

**Abstract.** In April 1996, an outbreak of toxic polyneuropathy in cats occurred in the Netherlands. All cats had been fed one of two brands of dry cat food from one manufacturer. Chemical analyses of these foods, stomach contents, and liver and kidney of affected cats revealed contamination with the ionophor salinomycin. Epidemiologic and clinical data were collected from 823 cats, or about 1% of the cats at risk. In 21 affected cats, postmortem examination was performed. The affected cats had acute onset of lameness and paralysis of the hindlimbs followed by the forelimbs. Clinical and pathologic examination indicated a distal polyneuropathy involving both the sensory and motor nerves.

*Key words:* Cat; peripheral nervous system; polyneuropathy; salinomycin; toxic.

Peripheral noninflammatory polyneuropathies are uncommon in domestic animals and generally are regarded as distal axonopathies.<sup>8</sup> The origin may be a number of conditions, including metabolic diseases like diabetes mellitus, hypothyroidism, and uremia; systemic disease; dietary deficiencies<sup>7</sup>; and intoxication with industrial agents, metals, and drugs.<sup>3,5,6,9,10,16,18–22,24–27</sup>

Polyneuropathies are particularly rare in cats, and those reported have been associated with diabetes mellitus,<sup>11</sup> myasthenia gravis,<sup>2,14</sup> and toxic substances<sup>15</sup> or were idiopathic.<sup>4,12,13,23</sup> The cases described by Gerritsen et al.,<sup>4</sup> Lane and deLahunta,<sup>12</sup> and Malik et al.<sup>13</sup> had an acute onset.

The purpose of this article is to present morphologic data related to the outbreak of acute polyneuropathy in cats in the Netherlands in April 1996. A short review of the epidemiologic and clinical data<sup>17</sup> is included.

### Materials and Methods

Epidemiologic and clinical data of 823 cats were collected from veterinary surgeons and owners of affected cats by telephone survey. Postmortem and histologic examinations were performed in 21 affected cats. Eight of these cats died spontaneously; the others were euthanatized because of severe respiratory dyspnea and/or no improvement of signs. The cats were submitted 1 day to 10 weeks after the onset of clinical signs. Tissue samples from all major organs, skeletal muscle, central and peripheral nervous systems (including the spinal nerves and ganglia), and the autonomic gan-

glia were fixed by immersion in 10% buffered formalin. Tissues were routinely dehydrated and embedded in paraffin. Sections were stained with hematoxylin and eosin (HE); additional stains used were phosphotungstic acid hematoxylin for heart and skeletal muscles and Holmes-luxol fast blue for the central and peripheral nervous systems. In selected acute, intermediate, and chronic cases, immunohistochemical testing for neurofilament protein (Euro-Diagnostica) was performed on sections from the central and peripheral nervous systems using the avidin-biotin-complex (ABC) method. The level of salinomycin in feeds and feed ingredients was determined by high-performance liquid chromatography using postcolumn derivatization essentially based on the method of Blanchflower et al.<sup>1</sup> To confirm test results, a special liquid chromatography-mass spectrometry method (LC-MS-MS) was also developed at TNO Nutrition and Food Research Institute. The latter method, which has an estimated accuracy of 30%, was also used to analyze salinomycin in stomach contents, liver, and kidney of selected cats.

### Results

#### Epidemiologic findings

During the first week of April 1996 (week 14), veterinary surgeons throughout the Netherlands were confronted with an unusually large number of cats with acute paralysis of the hindlimbs; in more severe cases, this was followed by paralysis of the forelimbs and eventually the respiratory musculature. Within 2 weeks, it became evident that all affected cats had been fed one of two dry cat food products from one

manufacturer with specific production dates. The public was immediately informed via the media. Not only the involved products but all dry cat food produced by the manufacturer and present in the market were recalled, and a major investigation of the cause of the disease was started. From this moment onward, a sharp decline in the number of affected animals was seen, and no new cases were encountered after 29 April (week 18) except for five cats that received food from the same batches (the retailer failed to return all the affected packages and accidentally sold these some weeks later). The total number of cats with acute paralysis reported in the Netherlands during this outbreak was 823. An estimated 100,000 cats were determined to be at risk (based on the number of packages sold and not returned), making the incidence of diseased cats about 1%. The age distribution of affected cats was normal. Although the number of males and females was almost equal, there were more males than females (3:2) in the severely affected group. The cats were mainly domestic shorthairs or crossbreeds; only about 5% were purebreds. Forty-four cats in Switzerland also developed acute paralysis, which was attributed to the same dry cat food products.

Because contamination of the food batches in question was most likely the cause of the outbreak, both the end product and the various components were examined for the presence of bacterial contamination, selected bacterial toxins, mycotoxins, coccidiostats, heavy metals, pesticides, organophosphates, strychnine- and cyanide-containing substances, selenium, and vitamin B1.<sup>10</sup> All tested substances except the coccidiostatic drug salinomycin were excluded. Further analyses revealed a concentration of 440 ppm salinomycin in the vitamin and trace element premix used for these batches and concentrations ranging from 13 to 21 ppm in the end products, to which the premix had been added at a level of 5%. The stomach contents ( $n = 1$ ) and liver and kidney ( $n = 3$ ) of animals that underwent postmortem examination within 24–48 hours after onset of clinical signs showed a signal upon LC-MS-MS analysis at the location of salinomycin at levels between 0.1 and 0.3 ppm; in the liver of another cat, salinomycin was not detected.

### Clinical findings

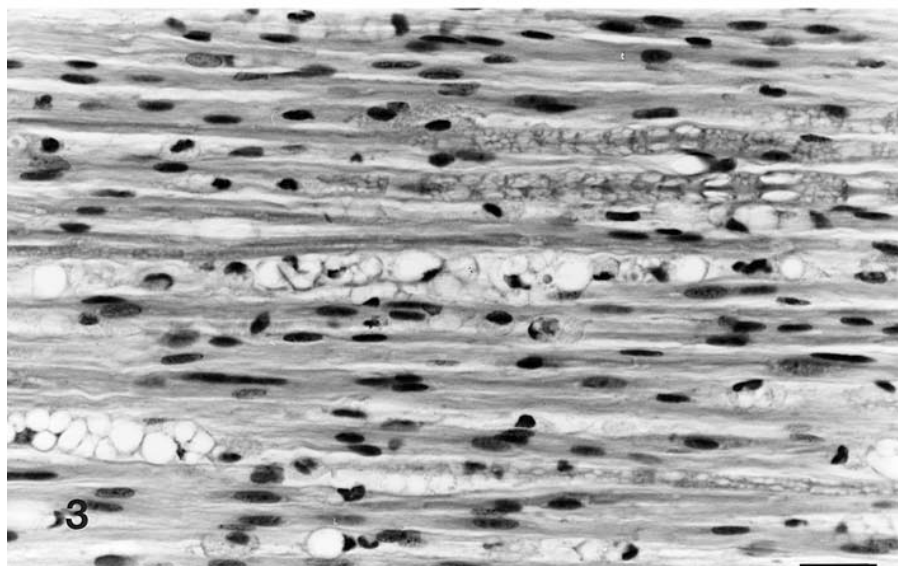
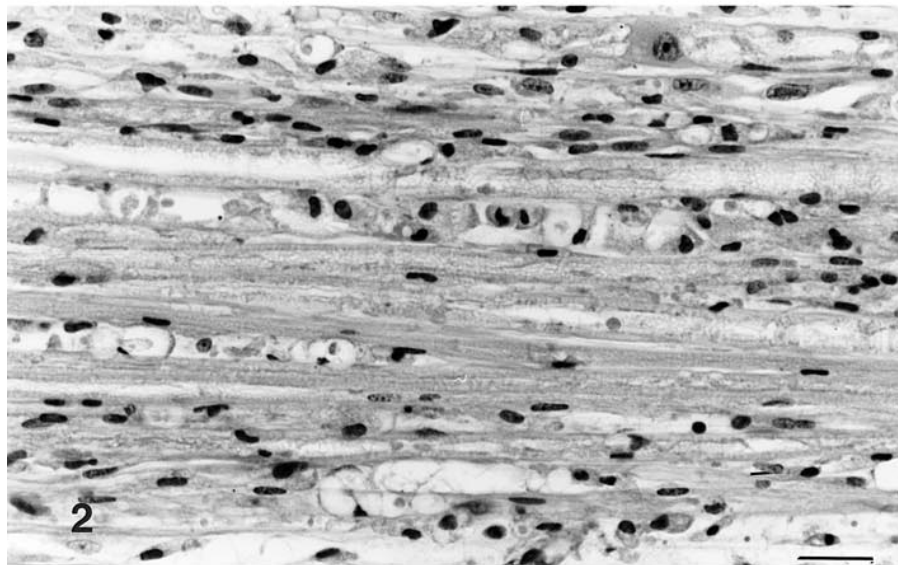
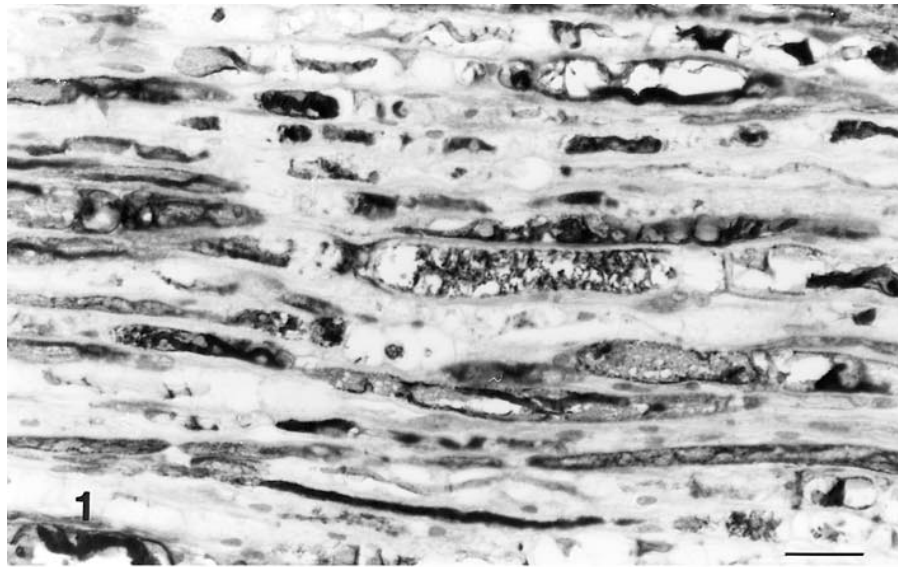
Seven affected cats were examined at the Department of Sciences of Companion Animals, Utrecht University. In four, tetraparalysis with marked dysphonia and dyspnea developed within 24 hours after the onset of clinical signs. Spinal reflexes were absent in the hindlimbs and strongly diminished in the forelimbs. Conscious pain perception was intact in all limbs. No signs of cerebral dysfunction were noted in any of the cats. The other three cats had posterior paresis and

slight muscular weakness of the forelimbs. Patellar reflexes were present but weak and they showed no dysphonia or dyspnea. Hematologic and serum biochemistry tests revealed no abnormalities except for a slight hypokalemia and leukocytosis in one cat. Electromyography showed fibrillations and positive waves (denervation potentials), particularly in the muscles of the limbs. Electrocardiograms taken in two cats showed no abnormalities. Symptoms mentioned by the veterinary surgeons and owners were in essence identical. In all cases, the onset of the paresis or paralysis was sudden and started in the hindlimbs, often with rapid extension to the forelimbs.

Two of the animals referred to the small animal university clinic died and were submitted for postmortem examination; the other animals improved and were released from the clinic after 2 weeks.

### Morphologic findings

In total, 21 cats were submitted for postmortem examination. They had died or were euthanatized at 1 (four), 2 (three), 4 (one), 5 (one), 6 (two), 7 (five), 9 (one), 10 (one), or 13 (one) days or 6 (one) or 10 (one) weeks after the onset of clinical signs. No gross abnormalities were observed except for the presence of a pale or pale-spotted heart in 20 cats and hemorrhage in the gastrointestinal tract due to an ulcer in the stomach in one cat. Microscopically, most severe abnormalities were found in the peripheral nerves of the forelimbs and hindlimbs. In the acute stage of the disease, up to 4 days after the onset of clinical signs, the lesions were characterized by widespread swelling, fragmentation, and loss of axons, although the myelin sheath still seemed to be intact (Fig. 1). After 4 days, axonal changes were accompanied by morphologic destruction of the myelin sheath with the formation of digestion chambers filled with foamy macrophages (Fig. 2). In the chronic cases at 6 and 10 weeks after the onset of clinical signs, the peripheral nerves had collapsed axon sheaths and sheaths filled with foamy macrophages (Fig. 3). In all cases, Schwann cells were swollen, and no inflammatory cells except for foamy macrophages were observed. Both motor and sensory nerves were affected. In nine cats, some Wallerian-type degeneration was seen in the dorsal funiculi of the spinal cord. No abnormalities were seen in the central nervous system of the other cats. In all cats, spinal and autonomic ganglia were normal. Slight to severe myocardial degeneration, the latter with hyalin degeneration and myocytolysis, was observed in all cats. Lesions were particularly located on the inner part of the left ventricle. In three cats, foci of hyalin degeneration with some macrophages were seen in the skeletal muscles.



## Discussion

The outbreak of acute paralysis in cats in April 1996 in the Netherlands and Switzerland was related to two brands of dry cat food from one manufacturer and was caused by contamination of the food with the coccidiostatic drug salinomycin. The paralysis was morphologically associated with a polyneuropathy of the peripheral nerves, characterized by primary axonal degeneration and secondary degeneration of the myelin sheath. Although some cats also had degenerative changes in the dorsal funiculi of the spinal cord, the lesions were restricted mainly to the peripheral nervous system. The myocardial degeneration observed may have been related to hypoxia of the myocardium due to dyspnea from paralysis of the respiratory musculature but also may have been a direct toxic effect of salinomycin. Cardiac damage caused by salinomycin and other ionophores has also been described in pigs, cattle, rats, and turkeys.<sup>26</sup>

The high frequency of myocardial changes observed during postmortem examination does not necessarily reflect the frequency in the total affected population, because the cats that underwent postmortem examination represent severe cases only. Clinical examination and electrocardiography in two cats revealed no evidence of cardiac abnormalities. Focal hyaline degeneration of the skeletal musculature was seen in only three of the 21 cats examined. This may be either a coincidental finding or one related to the toxic effect of salinomycin, but it definitely was not a characteristic finding in these cats.

Salinomycin is a polyether carboxylic ionophoric antibiotic. Like other ionophores, such as narasin (methylsalinomycin), lasalocid, and monensin, it is used in veterinary medicine as a coccidiostatic drug in poultry and as growth promotor in cattle. Safety studies have been performed in laboratory animals, farm animals, and dogs. There is marked variation in toxicity with respect to animal species and ionophore used. The dog appears to be the most sensitive animal species according to results of both acute and chronic toxicity studies.<sup>18</sup> Accidental intoxication with ionophores has been described in poultry,<sup>5,19,20</sup> turkeys,<sup>24</sup> horses,<sup>3,6</sup> sheep,<sup>16</sup> dogs,<sup>9,21,27</sup> and pigs.<sup>22,25</sup> No safety studies or accidental intoxications with ionophores in the cat have been described so far.

The primary target organ affected by toxic doses of ionophores are striated (skeletal and cardiac) muscles.<sup>18</sup> Degeneration of peripheral nerves has been reported in combination with muscular lesions due to lasalocid intoxication in chickens<sup>19</sup> and was found both with and without muscular lesions in subchronic and chronic toxicity studies in dogs treated with narasin.<sup>18</sup> Carboxylic ionophores promote an exchange-diffusion transport of cations across biological membranes. Salinomycin and other ionophores like narasin and monensin chelate monovalent cations (e.g., Na<sup>+</sup> and K<sup>+</sup>). Lasalocid chelates divalent cations. The facilitated transport of cations have effects on cellular function and metabolism because of changes in transmembrane ion gradients and electrical potentials. These changes are the basis of the known physiologic and toxicologic effects of ionophores.<sup>18</sup>

The clinical signs in our cats closely resemble those reported in an intoxication with lasalocid-contaminated food (166–210 mg/kg) in 10 dogs.<sup>21</sup> Those dogs had progressive paresis and paralysis of the hindlimbs often followed by quadriplegia and dyspnea. The onset of clinical signs was 6–12 hours after intake of contaminated food. Provocation tests with the contaminated food (two dogs) and with canned dog food mixed with lasalocid to final concentrations of 10 and 15 mg/kg (two dogs) caused identical clinical signs. These were attributed to the neuromuscular toxic effect of lasalocid, but because all animals survived after supportive treatment, no pathologic data were available.

Salinomycin intoxication caused the outbreak of acute polyneuropathy in cats in the Netherlands and Switzerland in 1996. The evidence is as follows. Carnivores may be more sensitive to ionophores than other animal species. Lasalocid at levels of 10–15 mg/kg provoke clinical signs in dogs similar to those seen in our cats. Peripheral neuropathy has been reported in relation with ionophore intoxication. The dry cat food associated with the outbreak of acute polyneuropathy contained salinomycin at levels of 16–21 mg/kg as contaminant, and detectable levels of salinomycin were present in the stomach contents and livers of cats that died 24–48 hours after the onset of clinical symptoms. The low incidence of affected cats, about 1% of animals at risk, may be explained by a combi-

←

**Fig. 1.** Peripheral nerve; cat. Swelling, degeneration, and fragmentation of axons. ABC method for neurofilament (NF). Bar = 23  $\mu$ m.

**Fig. 2.** Peripheral nerve; cat. Wallerian-type degeneration of the myelin sheath, characterized by digestion chambers filled with foamy macrophages. HE. Bar = 23  $\mu$ m.

**Fig. 3.** Peripheral nerve; cat. Chronic stage with collapsed axon sheaths and digestion chambers filled with foamy macrophages. HE. Bar = 23  $\mu$ m.

nation of factors: the presence of borderline toxic levels in the contaminated food, an uneven distribution of salinomycin in the food, individual variation in the amount of contaminated food ingested, and an inter-individual variation in sensitivity to salinomycin. These might also explain the absence of clinical signs in a provocation test in two adult domestic shorthair cats given the contaminated food.

### Acknowledgments

J. J. M. van Westerop and A. C. Tas are greatly acknowledged for their assistance with the salinomycin analyses. J. D. Van Amerongen is also acknowledged for his excellent preparation of tissues from the central and peripheral nervous systems.

### References

- 1 Blanchflower WJ, Rice DA, Hamilton JTG: Simultaneous high-performance liquid chromatographic determination of monensin, narasin and salinomycin in feeds using postcolumn derivatisation. *Analyst* **110**:1283–1287, 1985
- 2 Dawson JR: Myasthenia gravis in a cat. *Vet Rec* **86**:562–563, 1970
- 3 Gerhards H, Fenner A, Schoon HA: Monensin-Vergiftigung bei Equiden. *Dtsch Tierärztl Wschr* **93**:323–326, 1986
- 4 Gerritsen RJ, van Nes JJ, van Niel MHF, van den Ingh TSGAM, Wijnberg ID: Acute idiopathic polyneuropathy in nine cats. *Vet* **18**:63–65, 1996
- 5 Griffiths GL, Hillier P, Sutherland RJ: Salinomycin poisoning in point-of-lay turkeys. *Aust Vet J* **66**:326–329, 1989
- 6 Hanson LJ, Eisenbeis HG, Givens SV: Toxic effects of lasalocid in horses. *Am J Vet Res* **42**:456–461, 1981
- 7 Innes JRM, Saunders LZ: Deficiency diseases. *In: Comparative Neuropathology*, ed. Innes JRM and Saunders LZ, pp. 669–693. Academic Press, New York, NY, 1962
- 8 Jubb KVF, Huxtable CR: The nervous system. *In: Pathology of Domestic Animals*, Jubb KVF, Kennedy PC, and Palmer N, 4th ed., vol. I, pp. 267–439, Academic Press, San Diego, CA, 1993
- 9 Karsai F, Papp L, Sàyi G, Bagò GY, Kàntàs K: Gehauft auftretende Narazin-Vergiftigung bei Hunden. *Tierärztl Umschau* **45**:316–324, 1990
- 10 Kersten JGTM, Plekkringa RA, Verhagen H: A quest into finding the food-borne cause of cat paralysis. *Proc Euro FOOD Chem IX* **3**:778, 1997
- 11 Kramek BA, Moise NS, Cooper B, Raffè MR: Neuropathy associated with diabetes mellitus in the cat. *J Am Vet Med Assoc* **184**:42–45, 1984
- 12 Lane JR, deLahunta A: Polyneuritis in a cat. *J Am Anim Hosp Assoc* **20**:1006–1008, 1984
- 13 Malik R, France MP, Churcher R, McDonald B: Prednisolone responsive neuropathy in a cat. *J Small Anim Pract* **32**:529–532, 1991
- 14 Mason KV: A case of myasthenia gravis in a cat. *J Small Anim Pract* **17**:467–472, 1976
- 15 Nafe LA: Selected neurotoxins. *Vet Clin North Am Small Anim Pract* **18**:593–604, 1988
- 16 Nation PN, Crowe SP, Harris WN: Clinical signs and pathology of accidental monensin poisoning in sheep. *Can Vet J* **23**:323–326, 1982
- 17 van Nes JJ, Beynen AC, van der Linde-Sipman JS, van den Ingh TSGAM, Plekkringa R, Egberink H, den Hartog E, Seinen W: Epidemie van Alimentaire Polyneuropathie bij de kat. *Tijdsch Diergeneeskunde* **122**:604–607, 1997
- 18 Novilla MN, Owen NV, Todd GC: The comparative toxicology of narasin in laboratory animals. *Vet Hum Toxicol* **36**:318–323, 1994
- 19 Perelman B, Pirak M, Smith B: Effects of the accidental feeding of lasalocid sodium to broiler breeder chickens. *Vet Rec* **132**:271–273, 1993
- 20 Potter LM, Blake JP, Blair ME, Bliss BA, Denbow DM: Salinomycin toxicity in turkeys. *Poultry Sci* **65**:1955–1959, 1986
- 21 Safran N, Aizenberg J, Bark H: Paralytic syndrome attributed to lasalocid residues in a commercial ration fed to dogs. *J Am Vet Med Assoc* **202**:1273–1275, 1993
- 22 Salyi G, Glavits R, Molnar T, Cseplo A: Ionophor antibiotic poisoning in swine herds. *Magyar Allatorvosok Lapja* **49**:140–146, 1994 [English abstract]
- 23 Shores A, Braund KG, McDonald RK: Chronic relapsing polyneuropathy in a cat. *J Am Anim Hosp Assoc* **23**:569–573, 1987
- 24 Stuart JC: Salinomycin poisoning in turkeys. *Vet Rec* **113**:597, 1983
- 25 Vanhalderen A, Bastianello SS, Fouri N, Zumpt IF: An outbreak of narasin poisoning in swine. *J S Afr Vet Assoc* **64**:43–46, 1993
- 26 Van Vleet JF, Ferrans VJ: Myocardial diseases of animals. *Am J Pathol* **124**:98–178, 1986
- 27 Wilson JS: Toxic myopathy in a dog associated with the presence of monensin in dry food. *Can Vet J* **21**:30–31, 1980